

# A novel blue light diode laser (445 nm) for dental application

## Biomedical testing and clinical aspects

**Authors:** Prof. Dr Matthias Frentzen, Dr Dominik Kraus, Dr Joana Reichelt, Dr Christoph Engelbach, Dr Claudia Dehn & PD Dr Jörg Meister, Germany

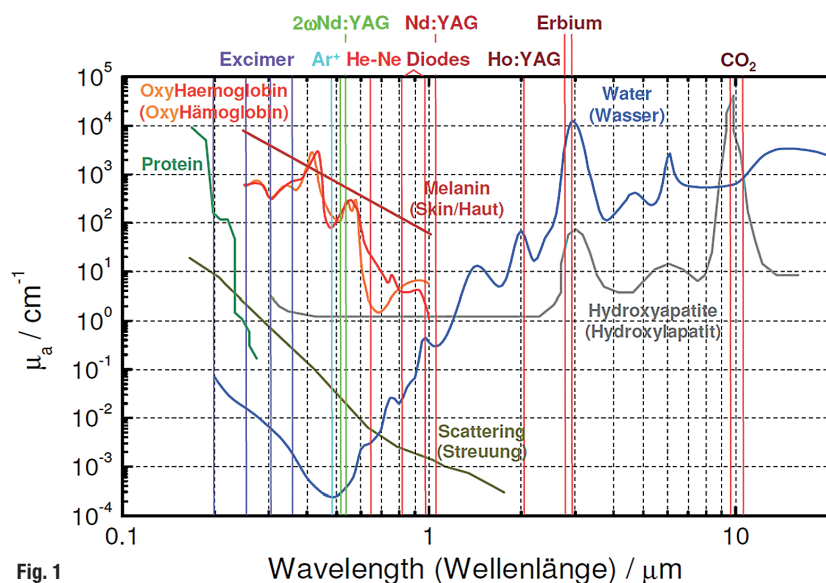


Fig. 1

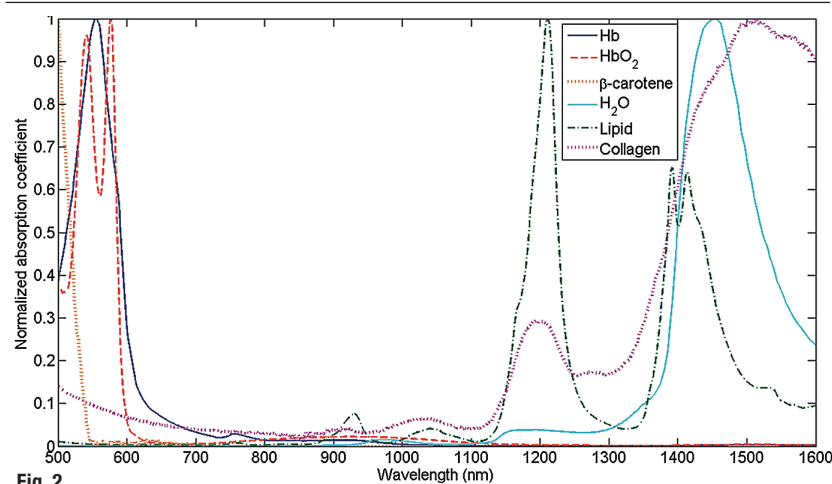


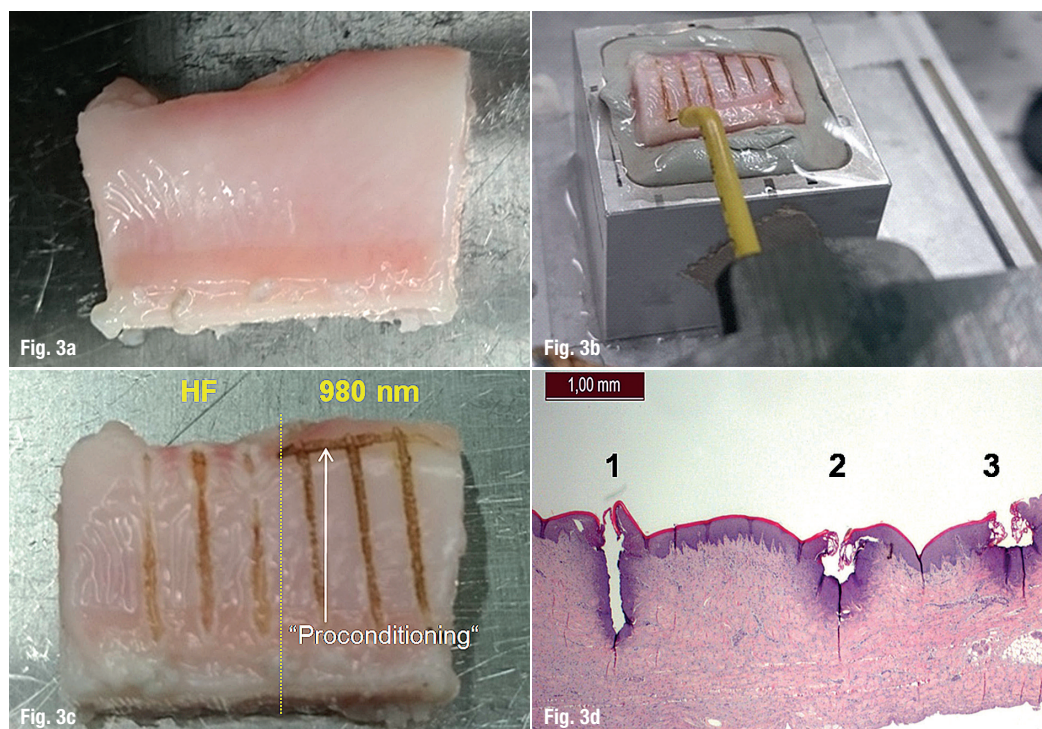
Fig. 2

The 445 nm laser represents an innovative extension to the already established diode laser systems. Improved cutting performance at a lower power level while retaining the advantages of the use of diode lasers for the treatment of oral soft tissue means that this is a further development in addition to the infrared systems with no apparent disadvantages.

### Introduction

In the last ten years, diode lasers—primarily in the near infrared spectrum (NIR, 800–1,000 nm)—have become established in dentistry on evidence-based fundamentals for surgical indications.<sup>1</sup> They are used primarily for the cutting and removal of oral soft tissue but also for the disinfection of gingival pockets<sup>2,3</sup> and root canals.<sup>4</sup> From a technical point of view, this technology is not particularly error-prone or expensive compared to gas or solid-state lasers and, when used correctly, the side effects can be easily assessed from the clinician's perspective.<sup>5</sup> The further development of laser diodes has enabled an expanded emission spectrum. As a result, laser application systems that emit in the blue light region are technically feasible nowadays.<sup>6</sup> From a biomedical point of view, these wavelengths provide significant advantages while maintaining an established technology. Blue light is already used clinically in a large number of medical indications.<sup>7,8</sup> As a result of the radiation

**Fig. 1:** Overview of absorption constants for different biological materials at different wavelengths. – **Fig. 2:** Absorption constants in the range of 500 up to 1,000 nm of soft tissue structures (according to 25).



**Figs. 3a–d:** Test setup for the implementation of standardised gingiva incisions:  
**a)** gingiva sample (mandibula, soft tissue and bone/pig);  
**b)** sample fixed on the optical bench;  
**c)** example of irradiated sample (HF versus 980 nm, 3W cw, 5 mm/s);  
**d)** histological section of Fig. 3c (HE-staining), 1: HF surgery, 2 & 3: laser 980 nm, 3W, cw.

output available up to now, surgical applications of the blue light lasers have not yet been realised to a significant extent. However, approaches to this have already been available in literature for a number of years.<sup>6,9</sup>

The modification of diode laser technology in dentistry towards systems with emission in the blue light spectrum can open a large number of advantages in comparison to the established diode laser technology in the NIR as a result of the biophysical properties. This includes, among others, a huge working effectiveness at considerably lower power settings. Because of this, for instance the side effects can be reduced considerably. Furthermore, there is a favourable effect on wound healing.<sup>10</sup> Antimicrobial effects are highly exceeded in comparison with infrared radiation and promote an effective disinfection of contaminated tissue areas.<sup>11–13</sup> In this way, the blue light may prevent wound infections. Clinical experience with radiation in the region of 450 nm is already available in many disciplines of medicine without any disadvantages of these wavelengths.<sup>14–16</sup>

### Biophysical properties of 445 nm laser radiation

The possible use of a laser application system with an emission wavelength of 445 nm for surgical procedures on oral soft tissues (incision/excision as well as bacterial decontamination and haemostasis) requires a high level of absorption of the radiation used in these tissues to work effectively. These are primar-

ily well perfused gingival tissues of the oral mucosa including the subepithelial connective tissue. Examples are the free gingiva, attached gingiva, alveolar mucosa, buccal mucosa, palatal mucosa, and mucosa of the tongue.

The absorption constant for a wavelength of 445 nm shows a high level of absorption in melanin and haemoglobin (Fig. 1). Furthermore, the absorption in collagen also increases significantly in the wavelength range of blue light (Fig. 2). Absorption in water, however, is lower compared to conventional NIR surgical diode lasers. In addition, scattering in the blue light spectrum also increases (Fig. 1). These biophysical effects mean that, in comparison to the infrared diode lasers, the working effectiveness may be considerably higher at the same power settings as a result of the huge increased absorption in the tissues. With regard to tissue vaporisation, intensive absorption may improve cutting effects. The increased level of absorption in comparison with conventional diode lasers could lead to a reduction of the thermal side effects outside the work area. The specific absorption constants related to blue light are therefore a basis for an effective limiting of biological side effects outside the radiation field.

The absorption of light at 445 nm in water is low. This means that, during surgical procedures, the radiation energy is almost completely transmitted through the non-pigmented mucin layer. Therefore, the cutting procedure starts immediately; there is no need for a so-called initialisation of the incision needed in cases by using diode lasers in the NIR.




The biophysical effects of blue laser radiation therefore favour the effective ablation of tissue from the beginning. Transmission properties and thermographic investigations confirm these observations: Transmission through agar layers of 3 mm thickness is approximately 80% at 445 nm, independent of the laser power from 100 mW to 1 W for irradiation periods between 5 and 20 seconds. The increase in temperature in this layer cannot be measured when the laser power is 100 mW, with a laser power of 1 W, a temperature increase of  $\Delta T = 2^\circ\text{C}$  could be observed. In contrary, in blood agar, high absorption ( $> 98\%$ ) and temperatures were measured. The comparison of the biophysical properties of laser radiation between diode lasers with wavelengths of 445 nm and 810–980 nm shows that in both cases photothermal effects are responsible for the laser-tissue interaction. On the basis of the laser settings that are technically possible, no non-linear effects, for example the formation of plasma, are assumed. The different absorption constants, however, support the vaporisation


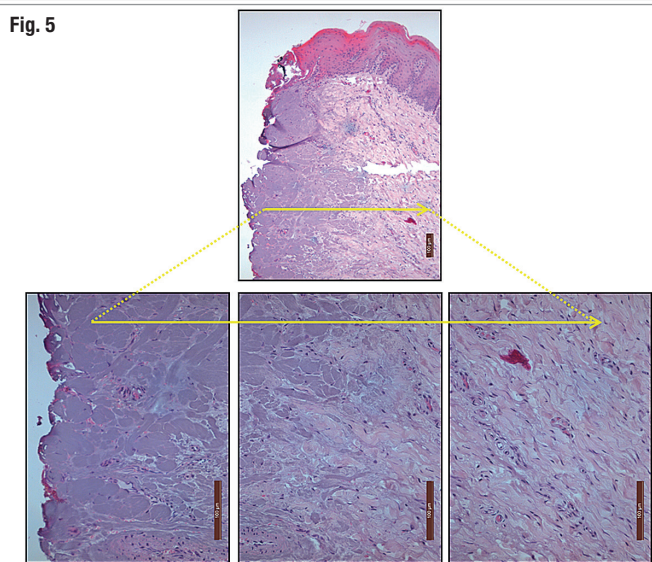
of oral soft tissue at 445 nm in comparison with IR lasers at 810 nm and 980 nm.

### *In vitro* investigations using a 445 nm diode lasers

Preparations from pig jawbones are particularly suitable as a model system for the investigation of the effects after laser irradiation under *in vitro* conditions. The macroscopic structure, the dimensions and the histological structure are very similar to human tissue so that valid statements can be made.<sup>17–22</sup> Gingiva preparations obtained from the vestibular mandibles of freshly slaughtered pigs were used for the investigation of the cutting effectiveness and histologically analysis of side effects during tissue preparation. They consisted of a rectangular segment of bone covered with gingival tissue (Fig. 3a). These samples were stored in physiological saline solution and were fixed to an optical bench immediately after removal (Fig. 3b). This bench was equipped with a linear micro-



**Fig. 4:** Ex vivo sample from pig gingiva after 445 nm laser incision (2W, cw). The high resolution photo collage shows that, starting from the surface, the morphology of the tissue has been preserved with a thin carbonisation film. No vacuolar structures and bleeding into the connecting tissue were detected. The incision edge is covered by a very small carbonisation layer. – **Fig. 5:** Detailed images of the subepithelial connective tissue after incision with 445 nm/2W, cw. An undermined blistering (tissue destruction) in the area of the lamina propria as is known with the 980 nm is only very slightly pronounced. The micromorphology of the tissue is preserved underneath the cutting level despite increased staining; no tissue haemorrhage was detected. – **Fig. 6:** Histological thin section after irradiation of a pig jawbone specimen using a 980 nm diode laser (2W, cw, left) and using a 445 nm diode laser (2W, cw, right), undecalcified thin section, staining: toluidine blue. With 980 nm, wide carbonisation zone with surrounding necrosis; with 445 nm, narrow carbonisation and necrosis zones.





**Figs. 7a–c:** Test setup and examples of the monolayer culture as well as the fluorescence detection of cytoskeletal changes and DNA double strand breaks:

- a)** sample mounted on a xyz-translation stage;
- b)** sample holder with coverslip;
- c)** laser incision of the monolayer with a 445 nm diode laser (2W, cw), thermal effects at the central irradiation zone (staining HE);
- d)** staining of the cytoskeleton after 445 nm laser irradiation with fluorophore conjugated phalloidine; no adverse effects (Alexa Fluor phalloidin, DAPI);
- e)** immunofluorescence microscopy: DNA double strand breaks characterised by red fluorescent foci (p-H2aX) occurs only after UV-irradiation as positive control.




Fig. 7a




Fig. 7b

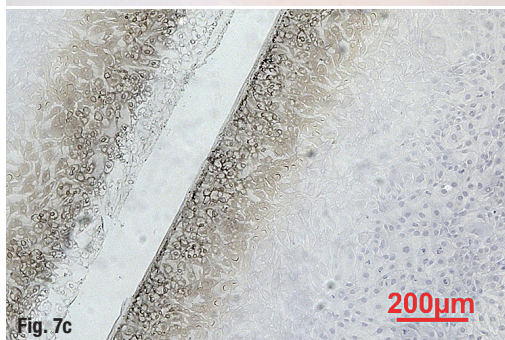


Fig. 7c




Fig. 7d

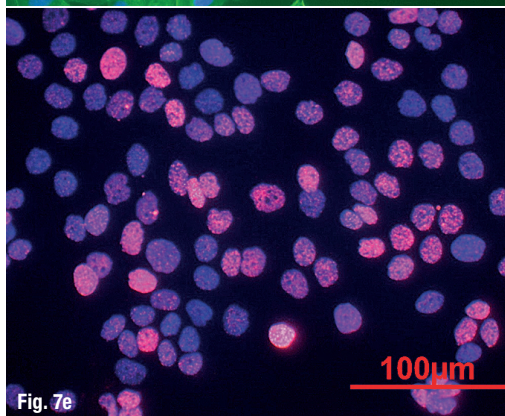


Fig. 7e

positioner that had been set to a feed rate of 1 and 5 mm/s to simulate constant cutting speeds. These cutting speeds were chosen to cover the spectrum of conventional laser applications. The specimens were irradiated using the same laser application system (diameter 320 μm) both with a wavelength of 445 nm and also with a 980 nm diode laser in contact mode. Linear incisions were carried out starting from the starting line that had been marked beforehand. The incisions were carried out with a 445 nm laser with a power of 1.5 and 2 W continuously and with a 980 nm laser with a power of 3 W in the same mode. Incisions that had been made additionally with a scalpel and with HF surgery served as references (Fig. 3c). From the gingiva of this sample, after removal of the soft tissue from the bone substrate, paraffin sections in HE-staining were examined under a light microscope (Fig. 3d).

The comparative histological evaluation of the specimens led to the following results:

1. The histological changes in the cutting area at wavelengths 445 nm and 980 nm are qualitatively identical.
2. The width of the coagulation zone and the cutting depth depends on the cutting speed (for both wavelengths and their parameters).
3. The width of the coagulation zone is, at the same cutting speed, larger at 980 nm compared to the 445 nm. With 445 nm, the width of the coagulation zone increases with rising power, in particular at a low cutting speed.
4. At a high cutting speed, the cutting depth is the same for 445 nm at 2 W and 980 nm at 3 W (output power).
5. The width of the coagulation zone is smaller with all 445 nm parameters than with 980 nm.
6. The HF surgical procedure led to histological results that are comparable with 980 nm.

With regards to "freehand" ex vivo procedures in pigs, 445 nm incisions (2 W, cw) demonstrated good cutting effectiveness and haemostasis for incisions of different depths (Fig. 4). Tissue vaporisation begins immediately after activating the laser. The working area remained clear due to haemostasis. The histological analysis (Fig. 4) shows three surgical incisions with differing depths. No mechanical effects (clefts/tissue deformation) were observed. The carbonising layer on the tissue surface treated is very narrow (approx. 1 μm). Around the incision, a zone of increased staining, which was clearly differentiated from the unchanged tissue, appeared. No undermining blistering was noted in the epithelium in the area of the cutting edge. The morphological structure of the tissue beneath the incision area is preserved despite the increased discolouration. Vessels in this area display no ruptures (Fig. 5). No red blood cells were detected outside of the vessels in the tissue.

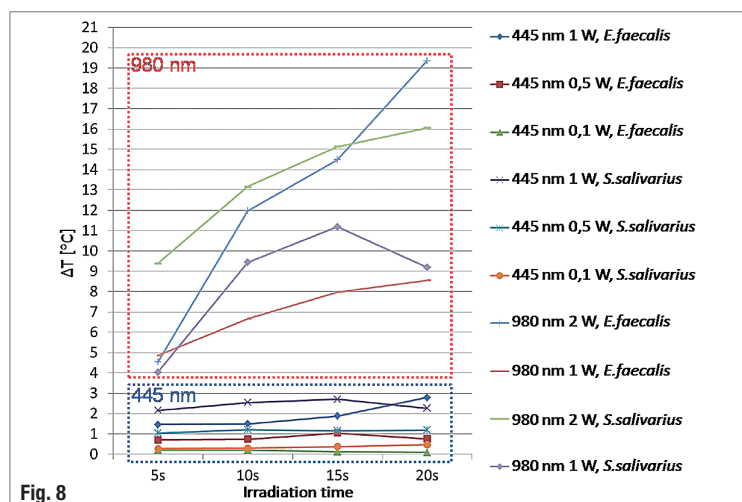


Fig. 8

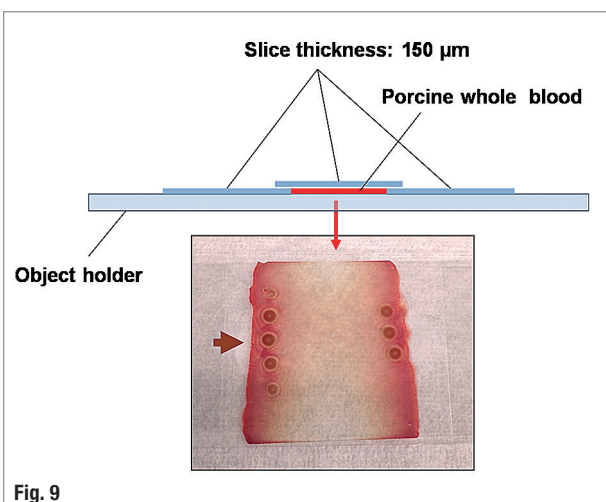


Fig. 9

In summary, it can be stated that, under "freehand" conditions ex vivo, only minimal carbonisation of the tissue was detected. Although the structures beneath this layer showed stronger histological staining, the tissue morphology was completely preserved. There is no detectable evidence of ruptures in the tissue or in the vessels. The results from these experiments indicate that the cutting efficiency at 980 nm with 3 W output power is at most about the same compared to the 445 nm at 2 W output power. The thermal damage zones and the proportion of carbonised tissue in the region of the cut appear more extensive when using 980 nm. In addition, the area of destruction of the epithelium (detachment of sub-epithelial connective tissue) lateral to the incision is larger when using 980 nm. The histological results correspond with the available literature when using 980 nm.

Irradiation of bone samples also show a considerably more pronounced carbonisation and necrosis zone with 980 nm compared to 445 nm (980 nm at 2 W, cw; 445 nm at 2 W, cw; Fig. 6). With NIR radiation, there is incineration on the surface with a pronounced carbonisation layer. It is connected to a wide necrosis zone. When comparing with the same cross-section specimen with 445 nm, there was a narrow carbonisation zone on the surface with an equally narrow necrosis zone beneath it.

## Cell culture trials

Diode lasers primarily induce thermal effects. However, regarding to a wavelength of 445 nm, only a few reports of the effect of laser radiation at the cellular level are available. The goal of cell culture studies therefore was to investigate the interaction effects of this radiation in comparison with the established IR infrared lasers. First, it was to be investigated whether the wound healing behaviour after laser application of 445 nm and 980 nm differed from that from mechanical interventions. Furthermore, it was to be in-

vestigated whether this laser radiation leads to specific cell damaging effects.<sup>23</sup>

For the simulation of oral soft tissues, HaCaT and MG-63 cells as monolayer cultures on cover slips were irradiated by diode lasers of wavelengths of 445 nm and 980 nm with power settings of 2 and 3 W in continuous wave operation (Figs. 7a–d). For the simulation of a surgical incision, linear irradiation with a defined traverse speed (3 mm/s) and a defined distance to the monolayer culture (1 mm) was applied. As reference, a mechanical wound was made with the laser application tip without the laser being activated (Figs. 7a–d). After irradiation, the morphology of the cells was documented using HE staining and the wound healing behaviour was assessed by light microscopy. The occurrence of cytoskeleton alterations and DNA double strand breaks after irradiation was analysed by using fluorescence staining (phalloidin, p-H2AX; Figs. 7a–d).

Using the 445 nm wavelength, thermal coupling occurred already at a power of 2 W, whereas at 980 nm this effect required a minimum output power of 3 W and a pigmented marking. Thermographic analysis indicated a considerably higher temperature increase on the monolayer surface during irradiation with 445 nm (> 400 °C) in comparison with 980 nm caused by the increased absorption of cells at 445 nm. The healing process of the lesions for both laser wavelengths in the monolayer are comparable to the mechanical injury (Figs. 7a–d). There was no evidence of an increased occurrence of double-strand breaks for both laser systems.<sup>23</sup> In contrast to UV irradiation as a reference, laser irradiation with both wavelengths did not increase the risk of DNA damages as an indicator for genetic risk (Figs. 7a–d).

## Antimicrobial effects

For many indications, an antimicrobial effect has also been attributed to laser irradiation of differing

**Fig. 8:** Temperature increase  $\Delta T$  (°C) after irradiation of cultures of *E. faecalis* and *S. salivarius* in agar plates at identical conditions with a 445 nm laser and a 980 nm laser in cw mode. The 980 nm laser causes a significantly higher temperature increase.

**Fig. 9:** Haemostatic effects of 445 nm laser irradiation. Coagulation of porcine whole blood (0.1 W, cw/non-contact mode, fiber to object distance 10 mm).



wavelengths. The basis for these effects are thermal and photochemical effects, e.g. known from aPDT (antimicrobial photodynamic therapy). This effect has been recognised for a number of years for NIR laser irradiation.

Studies in basic medical research have shown that blue light also has an antimicrobial effect.<sup>11</sup> As a result, a laser system with a wavelength of 445 nm has a significant potential for antimicrobial effects if such a laser is used within the scope of surgical indications.

Comparative studies were carried out whether the antimicrobial effect of a surgical blue light laser was comparable with the antimicrobial effects of infrared laser irradiation with a wavelength of 980 nm.<sup>24</sup> In particular, it was to be investigated whether decontamination of the surgical field with low thermal effects is basically possible. To test this, agar plates were coated with test bacteria (*E. faecalis* and *S. salivarius*) and irradiated with laser light at 445 nm and 980 nm. Identical application systems were used for this purpose. After laser irradiation, the agar was coated with an overlay agar that contained the specific nutrient components for the bacterial growth. Furthermore, the temperature of the irradiated area was measured using a thermographic camera during irradiation. Concerning the temperature change during the irradiation phase, only a small temperature increase had been observed when the laser radiation in the blue light spectrum was used. By contrast, there were significant temperature increases during irradiation with the 980 nm laser (Fig. 8). Under identical test conditions, bactericidal effects were demonstrated in the culture trials by the use of a 320 µm fibre diameter at 445 nm wavelength even at low output power (0.1 W) in non-contact mode.

At 980 nm irradiation, bacterial growth was firstly affected at 2 W output power. The effects were independent from the test species (*E. faecalis* and *S. salivarius*) that were used for this investigation. The results show a very high potential for a possible antibiotic treatment that can be achieved with only low-level stress to the region adjacent to the irradiated area—a maximum 3°C temperature increase in these investigations—in comparison to infrared laser irradiation. These results concur with a number of basic studies that assume a sustained antimicrobial effect of blue light.<sup>11-13</sup> This concomitant effect provides clinically relevant support for the use of a 445 nm laser for surgical indications.<sup>10</sup>

## Haemostasis

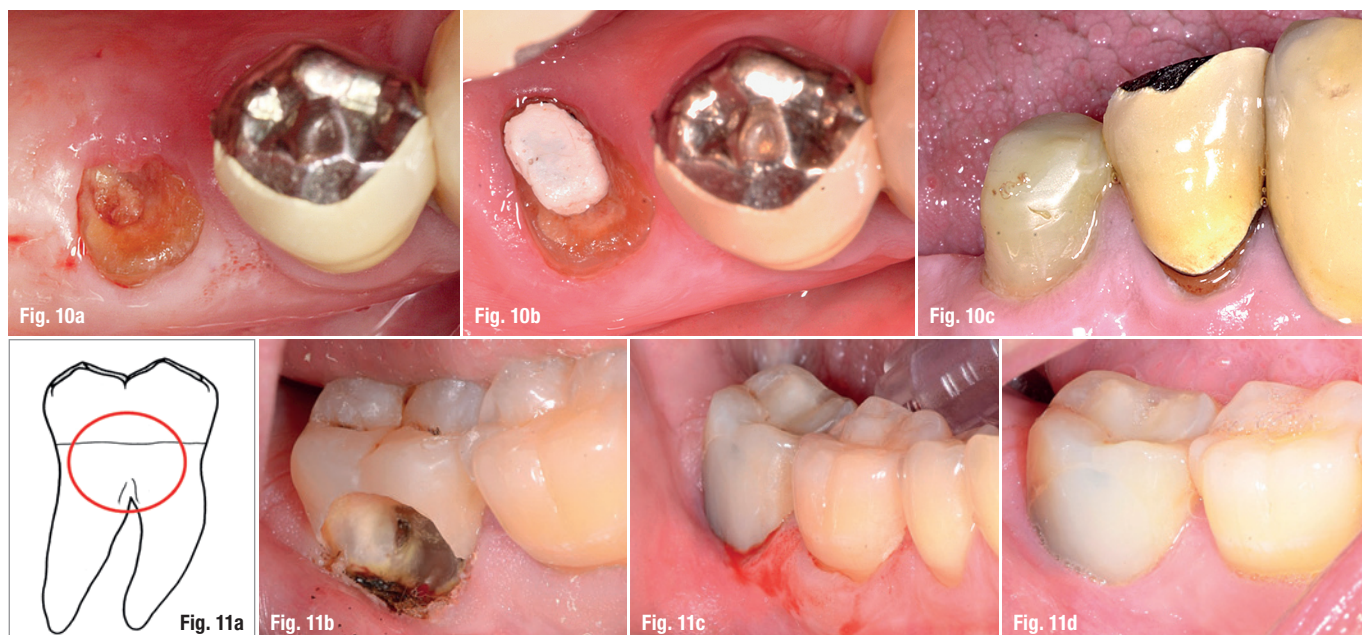Due to the strong adsorption of blue laser light in haemoglobin, pronounced coagulation effects were expected. To investigate coagulation, porcine whole blood in test samples with a thickness of 150 µm were examined (Fig 9). During irradiation with blue laser light, even with an output power of 0.1 W in cw mode, applied via a fibre with a diameter of 320 µm at an object distance of 10 mm, clearly visible coagulation effects occurred suddenly (Fig. 9).<sup>24</sup> These experimental results confirmed the prediction regarding the high haemostatic potency of the new blue light diode laser system (Fig. 1). This effect provides sustainable support to incision and excision procedures, in particular for patients with anticoagulation therapy.

## Case report of surgical applications

Based on the existing *in vitro* investigations, a clinical study was required to prove the particular properties of blue light laser radiation in clinical situations.

**Figs. 10a–c:** Deep crown fracture 45 in a multi-morbid patient; gingivectomy using 445 nm (1.5 W, cw, 320 µm Ø);  
**a)** OP situs before surgery;  
**b)** one week post-op;  
**c)** three months post-op.

**Figs. 11a–d:** Caries lesion up to the furcation area; adhesive restoration including endodontic treatment using 445 nm (1.5 W, cw, 320 µm Ø);  
**a)** location of the caries lesion,  
**b)** extensive excision of soft tissue, no bleeding after gingivectomy;  
**c)** adhesive restoration after finishing the margin of the cavity (removing of the carbonised layer with hand instrument);  
**d)** situation four weeks after vestibular composite restoration and endodontic treatment.



For this, a monocentric, prospective, randomised, two-arm, observer-blinded study was initiated, in which the effect of blue laser irradiation is compared with the established IR lasers with a wavelength of 980 nm (approval by the Ethics Committee of the Medical Faculty of the University of Bonn, No. 095/15). As part of these investigations, the clinical healing process after laser-based preprosthetic gingivectomies will be evaluated on the basis of a number of clinical assessment parameters. Among these parameters are bleeding on probing (BOP), sulcus fluid flow rate (SFFR), modified gingiva index (MGI), modified early wound healing index (mEHI) and attachment status. The laser parameters for the blue light laser were 2 W, cw and 3 W, cw for the 980 nm laser as these both power settings demonstrated comparable cutting efficiencies in pre-experiments. An identical handpiece with a 320 µm fibre was used for both lasers. Figures 10a–c shows examples of a gingivectomy after a crown fracture in a multimorbid patient (anticoagulants/diabetes). Figures 11a–d demonstrates the exposure of the marginal cavity margin in a patient with extended vestibular caries before root canal treatment. Figure 12 illustrates a comprehensive gingivectomy in a patient with idiopathic gingival hyperplasia.

Preliminary results from this study show that no adverse effects occurred either after the use of the 445 nm laser or after the use of the 980 nm laser. Wound healing was good with both lasers. In all of the cases that have been treated so far, no pain medication was necessary after the surgery. However, the 445 nm laser showed a higher level of cutting effectiveness that led to shorter operation times. Unlike the 980 nm laser, no fibre conditioning is necessary for the 445 nm laser wavelength. Furthermore, working in non-contact mode and periodic cleaning of the application tip improves the treatment outcome. In particular, it was determined that haemostasis was better with the 445 nm laser.

## Conclusion

The wavelength of 445 nm displays a high level of direct coupling to tissue during incision or excision that is achieved by the favourable biophysical properties of this radiation. Comparison of the cutting ef-

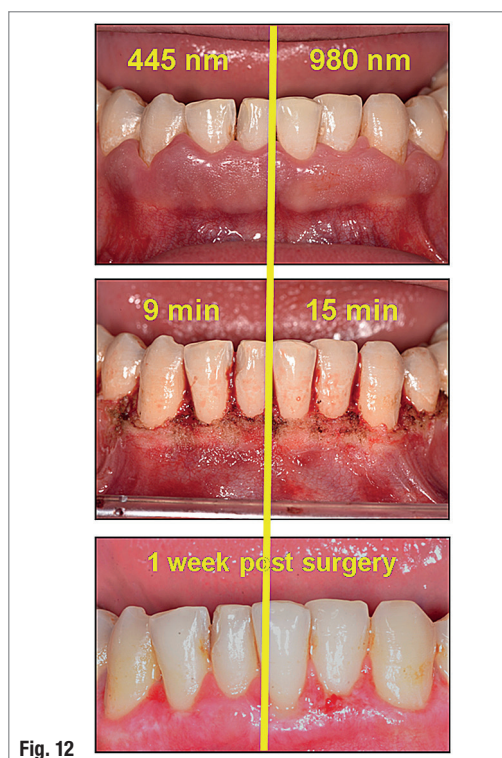


Fig. 12

**Fig. 12:** Gingivectomy in the lower jaw (idiopathic hyperplasia) using a 445 nm laser (1,5 W, cw, 320 µm Ø) and a 980 nm laser (3 W, cw, 320 µm Ø) in a split-mouth design. Surgical procedure using 445 nm was less time consuming.

fectiveness shows advantage effects with 445 nm in comparison to 980 nm. The consistent results from the histological investigations and the cell culture tests show that with both lasers tested, damage in the sense of an unspecific thermal interaction occurs. Therefore, modification of the emission wavelength of the diode laser does not shift the risk of application. No disadvantages in comparison to the already established IR diode lasers were found. Modifying the wavelength thus represents an advancement with clinical relevance regarding a desired range of indications (incision/excision/disinfection).

## contact

Center for Dental, Oral and Maxillofacial Dentistry  
(Zentrum für ZMK) Bonn/AG Laser in der Zahnheilkunde  
(Lasers in Dentistry working group)  
Welschnonnenstraße 17  
53111 Bonn, Germany  
[www.amlarebo.uni-bonn.de](http://www.amlarebo.uni-bonn.de)

## Kurz & bündig

Der 445 nm-Laser stellt eine innovative Alternative zu den bisher etablierten Diodenlasersystemen dar. Eine verbesserte Schnittleistung bei geringerem Leistungseinsatz unter Beibehaltung der Vorteile der Anwendung von Diodenlasern im Rahmen oraltherapeutischer Maßnahmen am Weichgewebe bedeutet eine Weiterentwicklung der Infrarotsysteme, ohne dass Nachteile erkennbar sind.

Literature

